

## MANAGEMENT OF PENILE ZIPPER INJURY

R. FLOWERDEW, I. J. FISHMAN AND B. M. CHURCHILL

*From the Division of Urology and the Department of Anesthesia, The Hospital for Sick Children, Toronto, Ontario, Canada.*

### ABSTRACT

A penile problem that physicians are confronted with in the emergency room is entrapment of the foreskin by a zipper fastener. A case presentation and a simple technique for its management are described.

A 3-year-old boy was brought to the emergency room after his mother had accidentally trapped the penile prepuce between the fastener and the teeth of the zipper while undressing him. After several painful and fruitless attempts to free the entrapped foreskin she cut the zipper from the pants (fig. 1) and brought the child to the hospital. The child was anes-

thetized because of extreme anxiety and poor cooperation. Separation of the zipper fastener from the teeth with release of the entrapped skin was accomplished by squeezing the median bar of the zipper with a bone cutter. There was minimal trauma to the foreskin and the child was sent home the same morning.

Management of this problem has included circumcision<sup>1</sup> or extraction of the foreskin by manipulation.<sup>2</sup> Problems with circumcision include pre-existing local edema, lack of psycho-

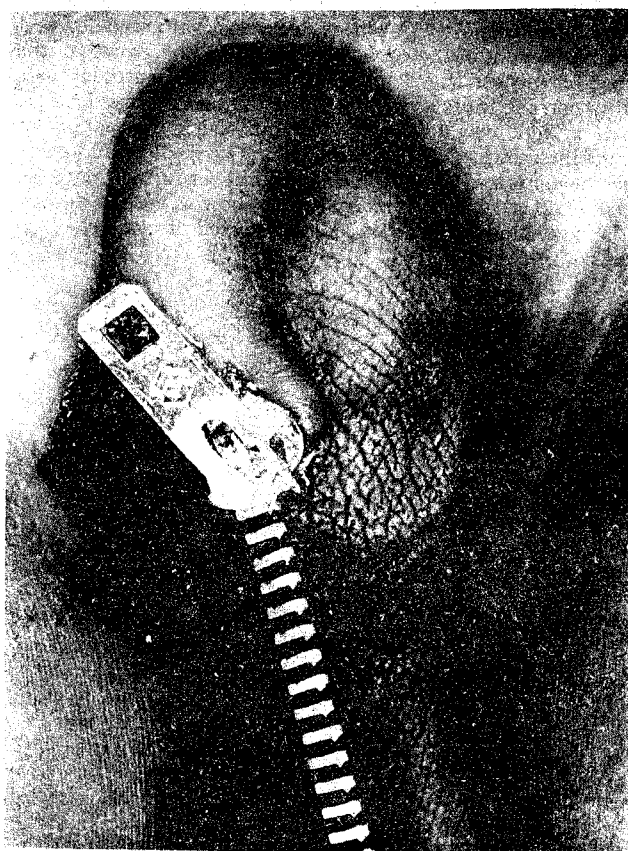


FIG. 1

thetized because of extreme anxiety and poor cooperation. Separation of the zipper fastener from the teeth with release of the entrapped skin was accomplished by squeezing the median bar of the zipper with a bone cutter. There was minimal trauma to the foreskin and the child was sent home the same morning.

### DISCUSSION

Entrapment of the foreskin between the fastener and the teeth usually occurs when the zipper is being opened because

Accepted for publication November 19, 1976.  
Read at annual meeting of Northeastern Section, American Urological Association, Hot Springs, Virginia, September 19-23, 1976.

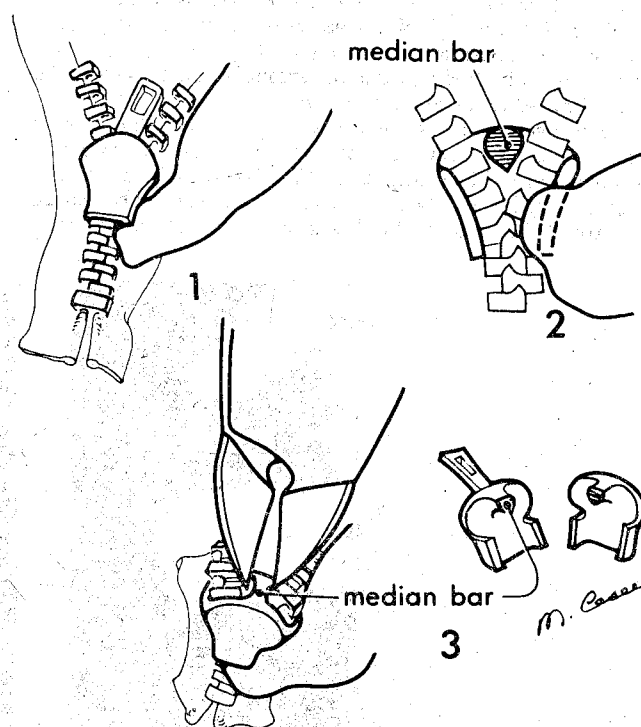


FIG. 2

logical preparation and possible cultural and/or individual taboos. Extraction by manipulation usually is prolonged, painful and often non-productive.

We suggest the following approach. A bone cutting plier is applied to the median bar (fig. 2). Squeezing this bar will permit the whole zipper to fall apart and release the entrapped skin. If this maneuver is applied initially a cooperative and grateful patient is the result. However, previous attempts to extract the foreskin, especially in young children, may have already caused considerable pain and, therefore, will require either local or general anesthesia.

### REFERENCES

1. Watson, C. C.: Zipper injuries. *Clin. Pediat.*, 10: 188, 1971.
2. Ezell, W. W., Smith, E. I., McCarthy, R. P., Thompson, I. M. and Habib, H. N.: Mechanical traumatic injury to the genitalia in children. *J. Urol.*, 102: 788, 1969.